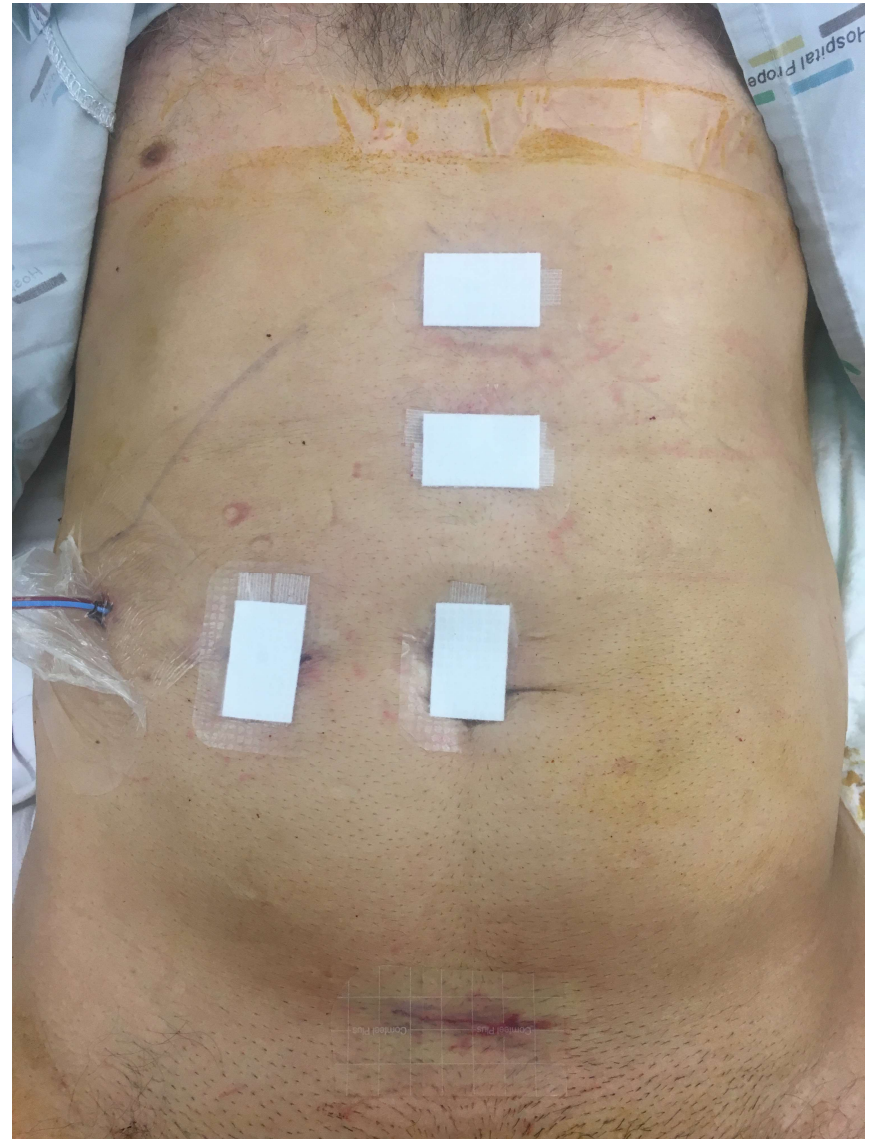
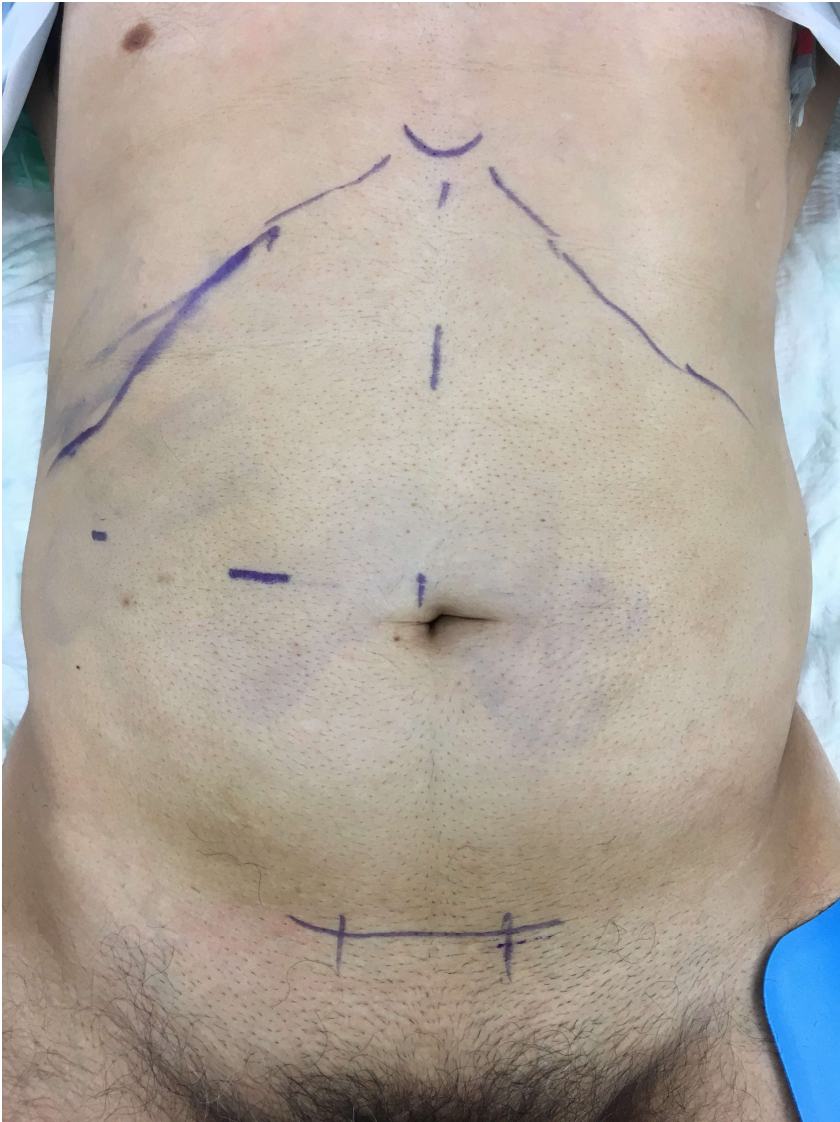
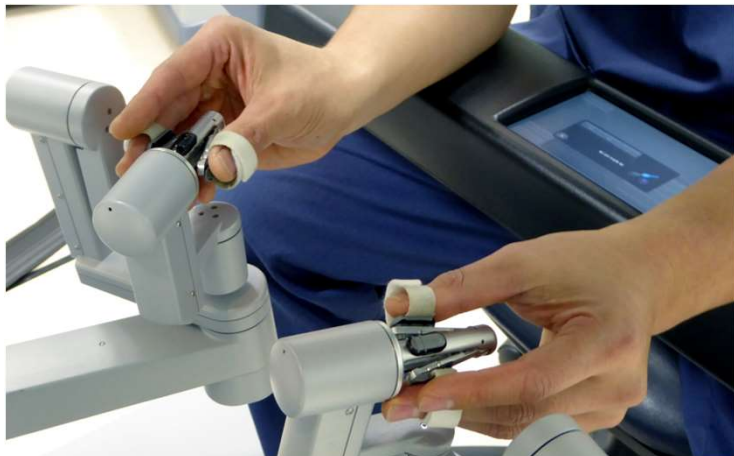
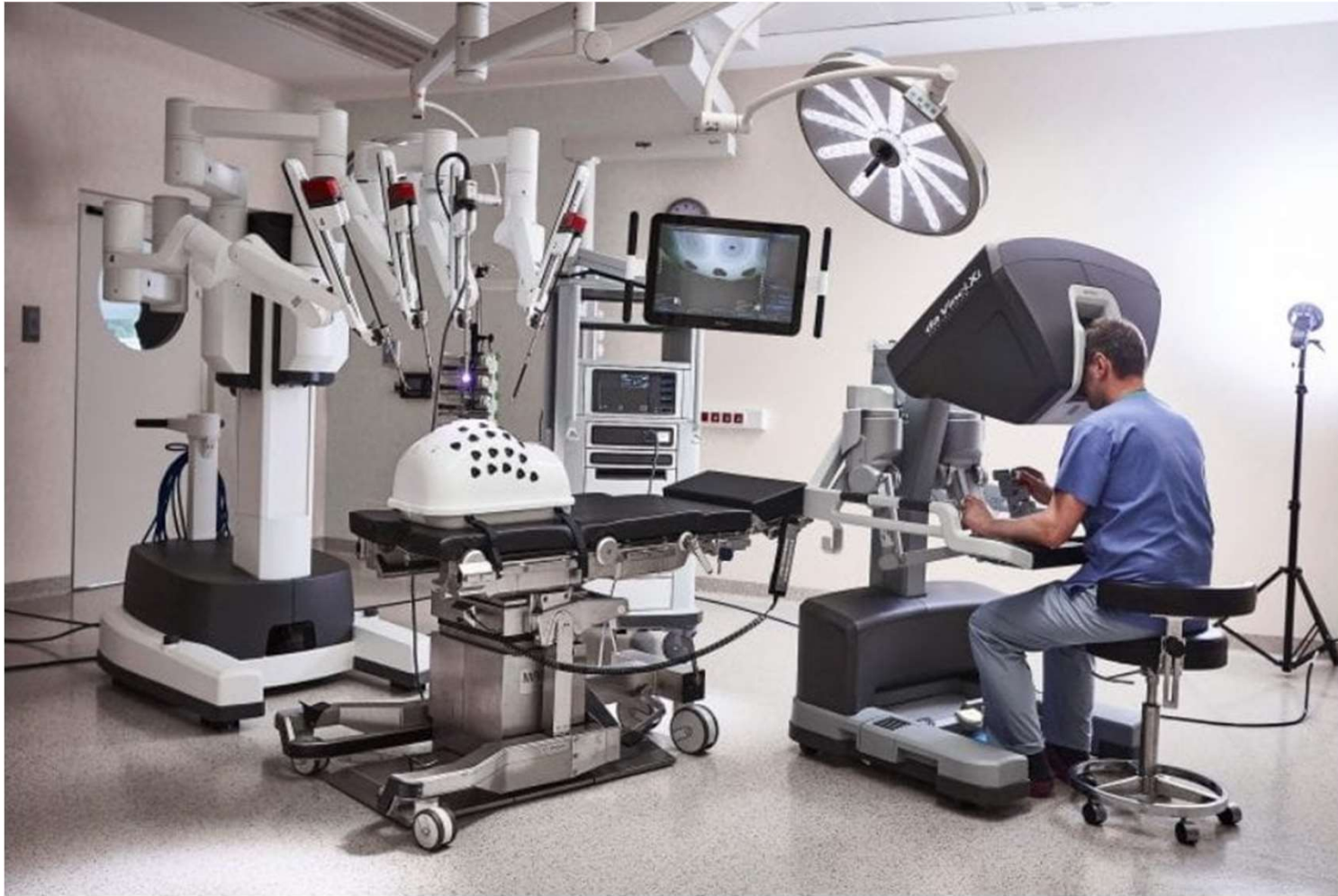
Laparoscopic liver resection

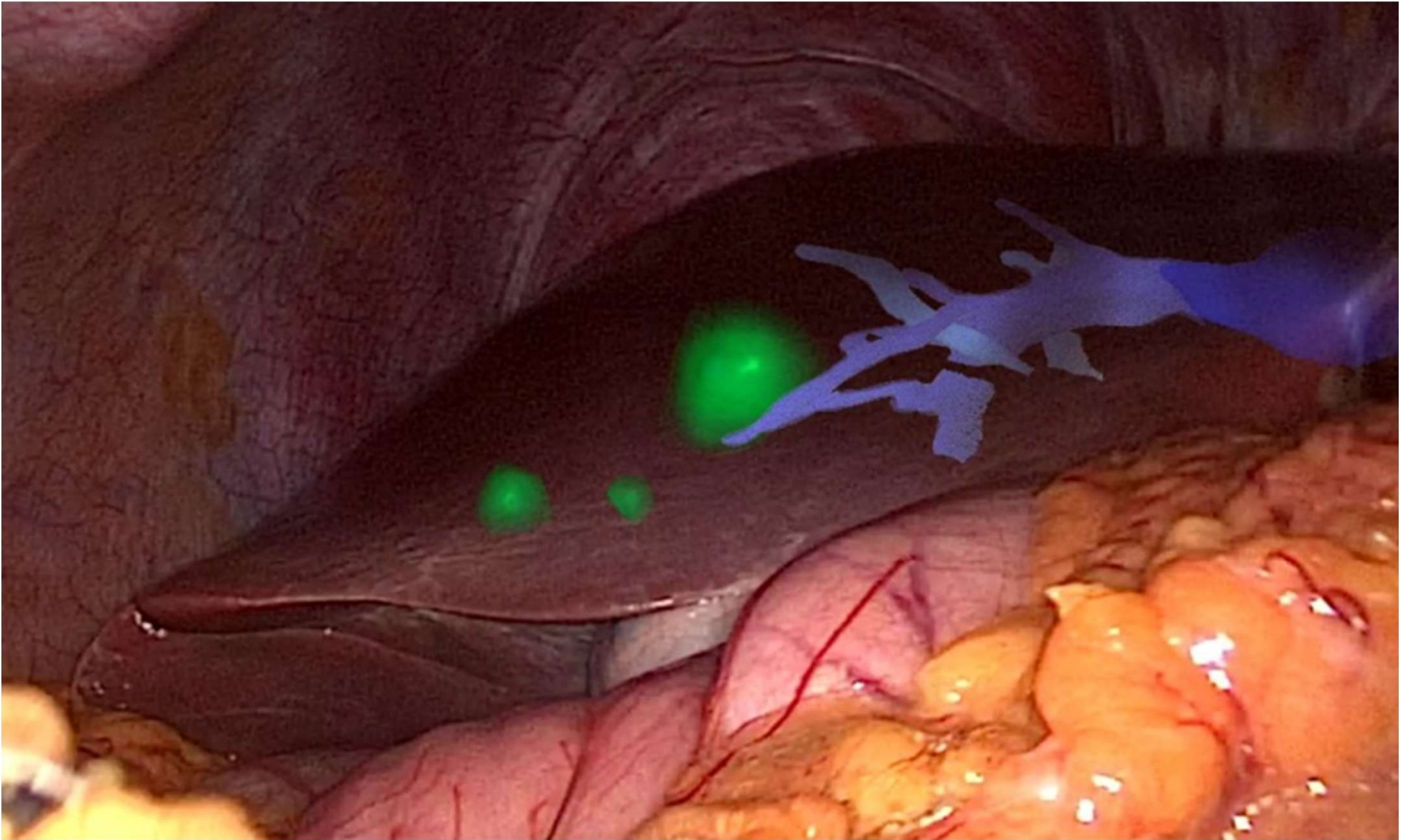


Incisions for laparoscopic right hepatectomy



Da Vinci Robot
Intuitive Surgical

Augmented Reality



Outcomes of Liver Cancer Resection

Cancer	5-year survival	Comments
Hepatocellular Carcinoma	25-50%	Dependant on underlying liver disease Transplantation may be option
Hilar cholangiocarcinoma (Klatskin)	20-40%	Difficult to resect due to location
Intrahepatic cholangiocarcinoma	10-50%	Often present late/unresectable
Colorectal metastases	50%	Median OS 3yrs, 20% “cure”
Neuroendocrine metastases	50-80%	Cure rare but patients can live with disease for a long time
Other metastases	Variable	Generally poor outcomes after resection - select patients case by case

Case study

Case Study - Ms A

Multistaged liver resection

- 35 year old woman presented in Oct 2020 with an obstructing rectal cancer with contained perforation
- Numerous large liver metastases

Initial presentation

