

The Snoring Adult

Angus Shao
FRACS ORL-HNS
EAFPS

The snoring adult

- Definition of OSA differs
- From Habitual snoring to severe OSA

Assessment


- STOPBANG score
- Epworth scale
- History from partner, occupation, comorbidity
- Examination

Examination

Body BMI

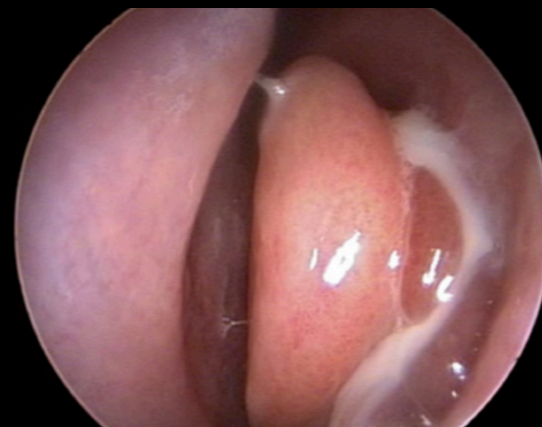
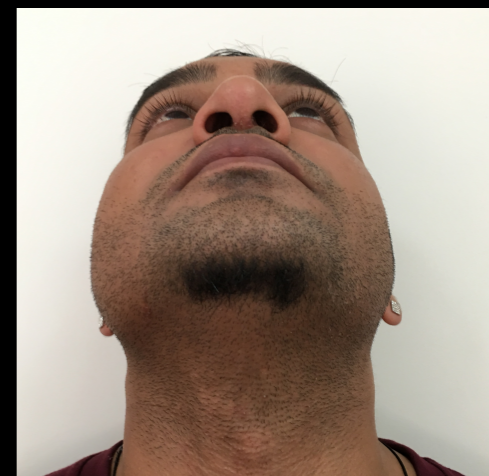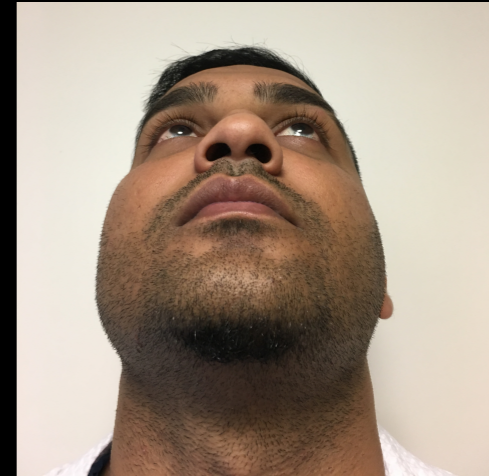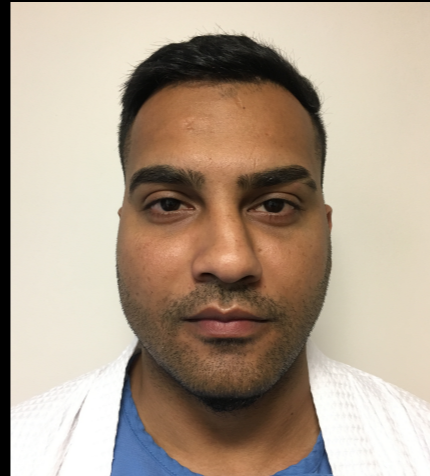Cranial facial anomaly

Neck Circumference



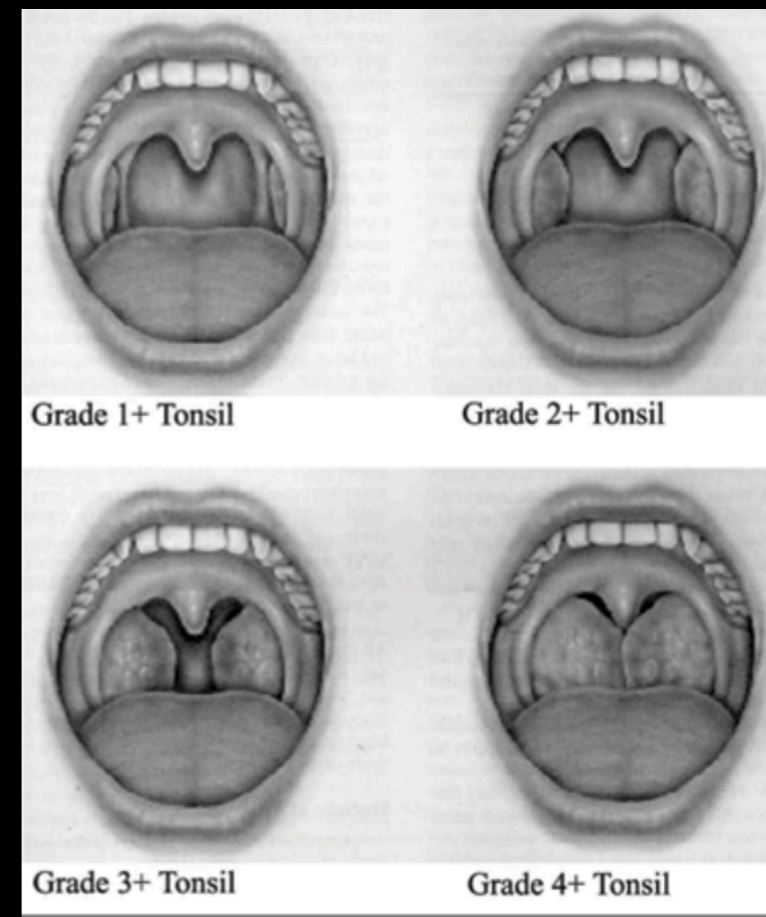
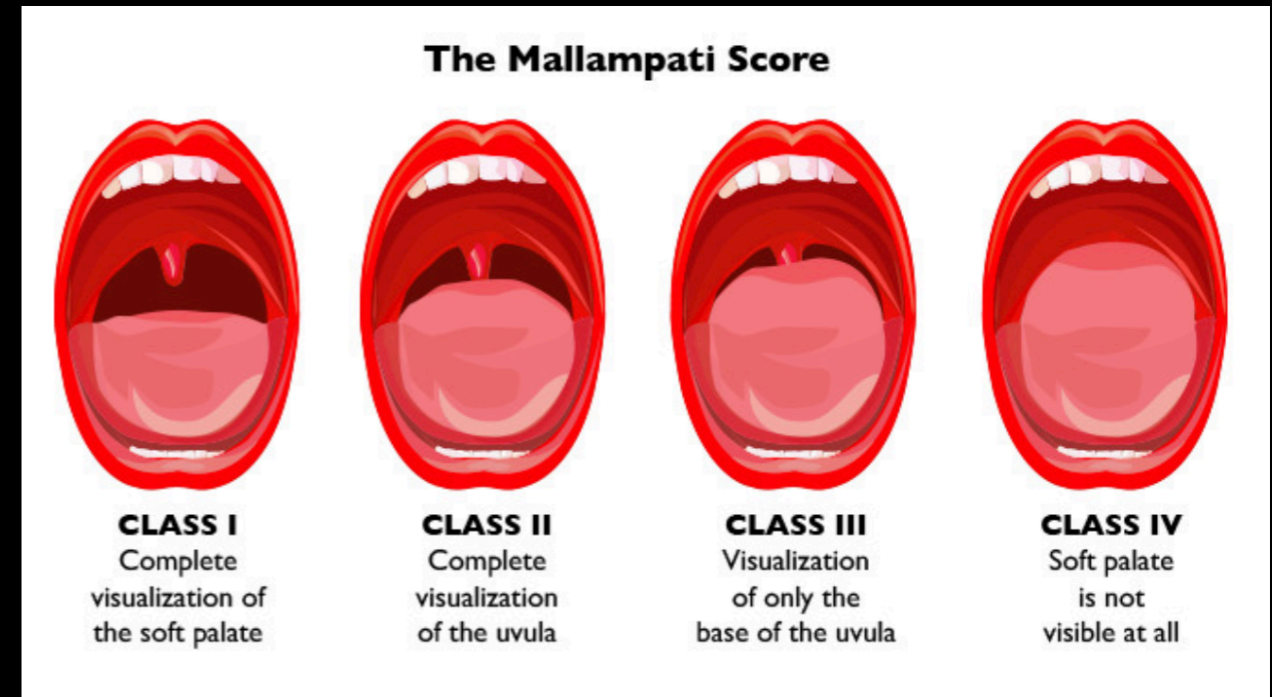
Examination

Nose



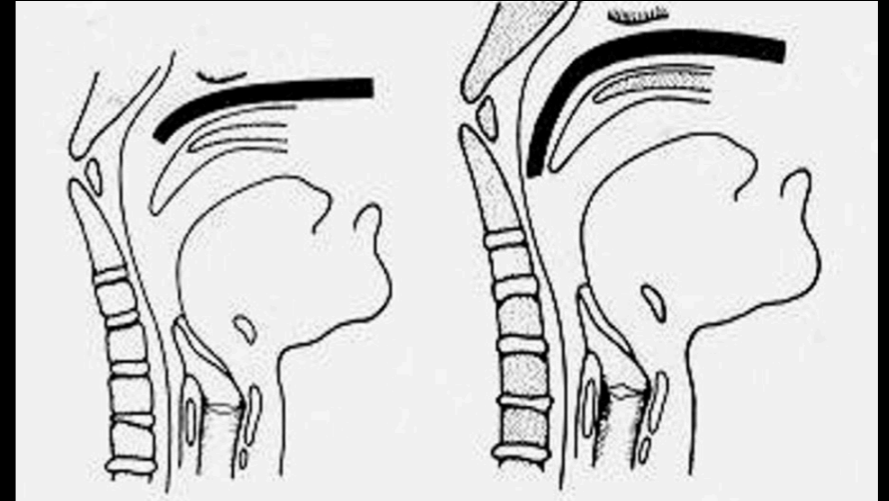
Examination

Oral Cavity

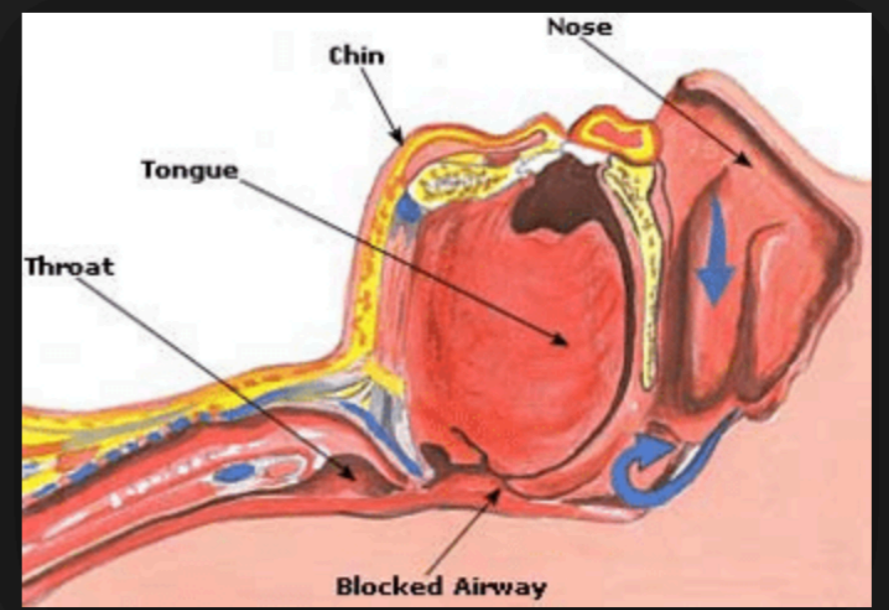


Examination

Throat

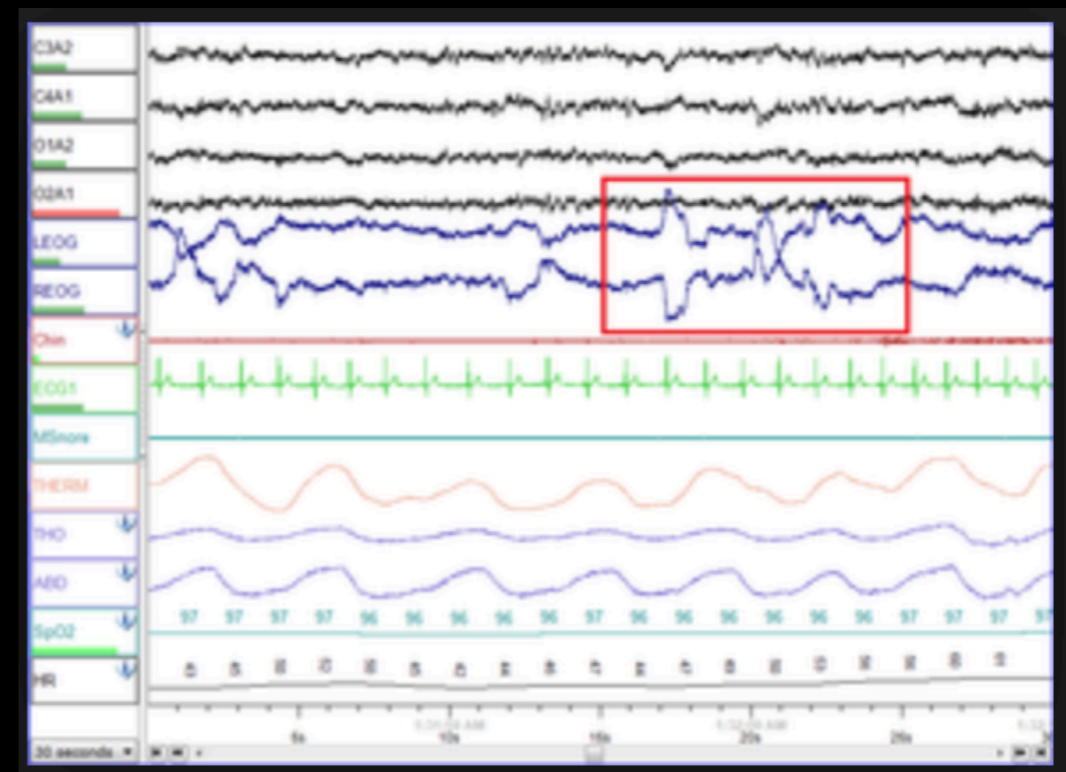
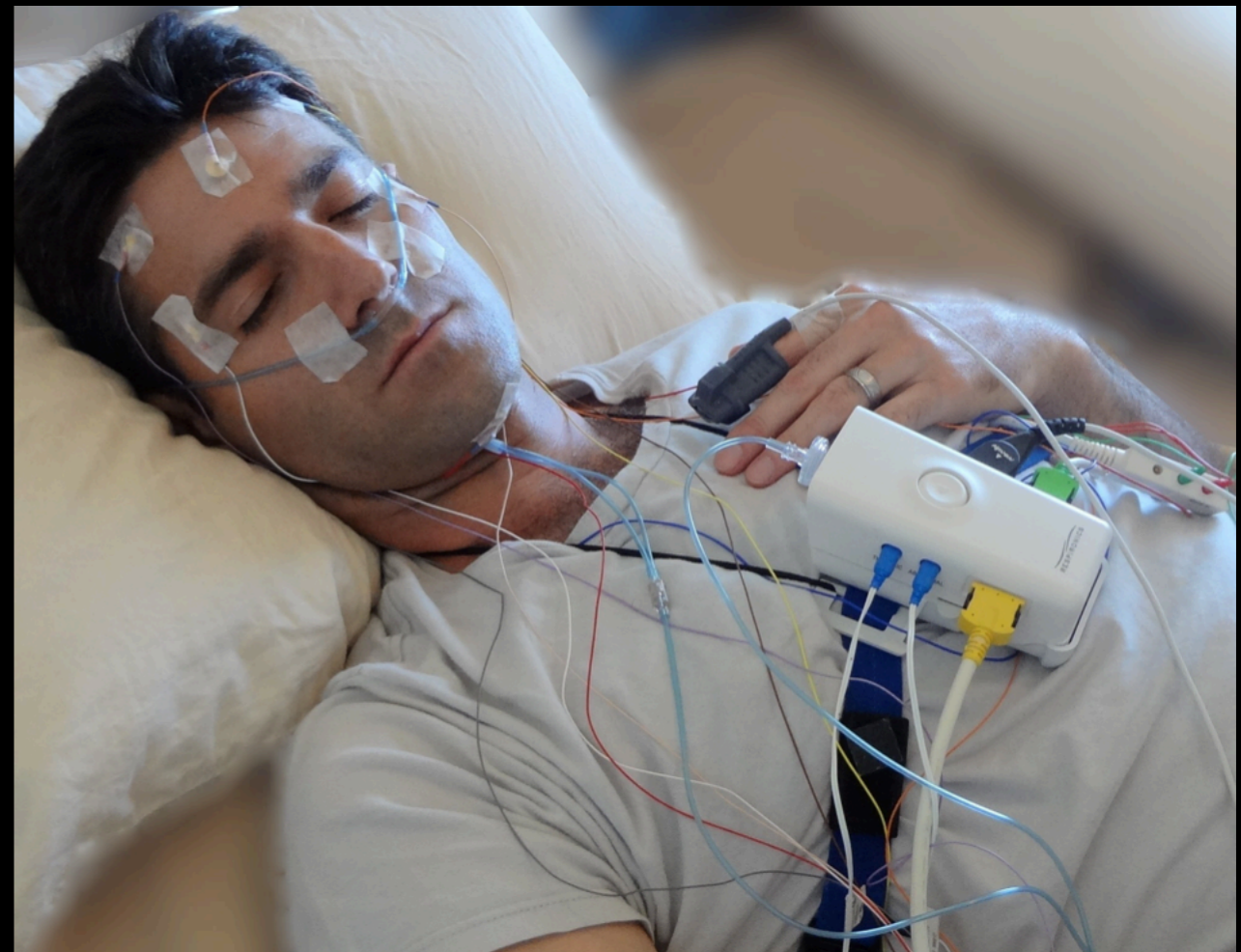

Mueller's maneuver: Fiberoptic endoscope positioned just above (L) and below (R) oropharyngeal inlet.



Investigation

PSG
DISE



Treatment

